



Published by DiscoverSys

Improving the quality of positioning and reducing the rotation factor during pediatric portable chest radiography using infant immobilizer



CrossMark

Alireza Mahmoudabadi,¹ Majid Sadeghi Moghadam,^{2*} Moosa Sajjadi,³ Majid Shams,⁴
Leila Ameri⁵

ABSTRACT

Background: The portable chest X-ray in infants hospitalized in neonatal intensive care units is one of the most common diagnostic procedures. Every child during hospitalization period may be incurred over a number of portable chest radiography examinations. Optimization of the infant position for radiography results in the improved diagnostic quality of radiographs.

Objective: To evaluate rotation factor during pediatric portable chest radiography; the present study examined the effect of two different methods to stabilize infant position during radiography on the incidence of rotation.

Materials and methods: This is an interventional study with nonequivalent groups in which rotation factor was evaluated on 250 portable chest radiography on fields of newborns admitted to NICUs (in two intervention and control groups), by comparing the length of posterior ribs on both sides of the chest. In this study, 176 radiographs were related to infants from three university hospitals so that sandbags or patients accompany had been used to stabilize the

position of the patient, and 74 radiographs were for infants referred to an academic center whose positions had been stabilized during X-ray using body immobilizer.

Results: The mean difference between the length of right and left posterior ribs in infants stabilized with the usual method (sandbags or patients accompanies) was obtained 6.51 ± 5.05 mm. This statistical index for the second group of infants whose positions had been stabilized through body immobilizer was 2.87 ± 2.15 mm. Independent t-test showed a significant difference between the two groups in terms of the difference in the quantity of rotation. In this study, the difference in the length of posterior ribs over 5 mm was found as detectable rotation in the images.

Conclusion: The infant position during radiography can be improved considerably by using proper body immobilizer, and repeating the tests can be avoided due to the inappropriate position. By means of such an instrument, there is no need for the help of accompanies or personnel to stabilize infant position, and their exposure will be prevented.

Keywords: Infant Immobilizer, Chest radiography, Positioning, Rotation

Cite This Article: Mahmoudabadi, A., Moghadam, M.S., Sajjadi, M., Shams, M., Ameri, L. 2018. Improving the quality of positioning and reducing the rotation factor during pediatric portable chest radiography using infant immobilizer. *Bali Medical Journal* 7(2): 420-425. DOI:10.15562/bmj.v7i2.737

INTRODUCTION

Recent studies in the past decade have shown that the world's preterm birth rate has risen steadily so that 12.6% of the total annual births in America accounts for preterm infants less than 36 weeks. Most of these newborns are hospitalized in the Neonatal Intensive Care Units due to some reasons such as poor body, physical disorders and underlying diseases.¹

These patients during hospitalization in the NICU are repeatedly being examined by portable chest radiography.²⁻⁴ The reason is that the portable chest radiography is a simple, accessible and low-cost test that can reveal a wide range of diseases in pleura, lung parenchyma, and thoracic skeletal structures, as well as some mediastinal problems. Furthermore, the pediatric portable chest radiography is also employed to check the position of catheters and tubes placed in the patient's body for

diagnostic or therapeutic purposes, provided that the performed X-rays have the required diagnostic quality.⁵

High-quality diagnostic radiography requires the use of proper exposure technique, the standard position of an infant during radiography and suitable method of imaging.⁶

Unfortunately, there is no standard chart to guarantee the quality of graph for the exposure conditions. The exposure conditions are set based on the experience and skills of the radiographer. In the imaging using screen/film system due to its low dynamic range, increase or decrease in exposure severely affects the final quality of the image and can be followed by a repeated test. However, the two basic types of digital imaging systems including Computed Radiography (CR) and Direct Radiography (DR) have wide dynamic range, so

¹Assistant Professor of Radiology, Medical Physics Department, Faculty of Medicine, Gonabad University of Medical Science, Gonabad, Iran.

²Msc of Medical Physics, Medical Physics Department, Faculty of Medicine, Gonabad University of Medical Science, Gonabad, Iran. (Corresponding author)

³Assistant Professor of Nursing, Department of Medical-Surgical Nursing, Faculty of Nursing & Midwifery, Gonabad University of Medical Sciences, Gonabad, Iran.

⁴Radiologist MD, Bohlool Hospital, Gonabad University of Medical Science, Gonabad, Iran.

⁵Radiologist MD, Qaem Hospital, Mashhad University of Medical Science, Mashhad, Iran

*Correspondence to:
Majid Sadeghi Moghadam, Msc of Medical Physics, Medical Physics Department, Faculty of Medicine, Gonabad University of Medical Science, Gonabad, Iran. (Corresponding author)
sadeghim881@gmail.com, majid.sadeghimoghadam@chmail.ir

that defects in improper exposure can be corrected somewhat in the post-processing, and the final contrast of the image can be improved. For this reason, screen/film imaging systems currently are being replaced quickly through CR and DR.^{3,6}

Another important factor affecting the diagnostic quality of the image is the correct position of an infant during radiography. Stabilization of newborns position during radiographic procedures induces radiography quality improvement and reduces rotation and movement artifact. The aim of this study is an evaluation of rotation factor in chest radiography of newborns hospitalized in NICUs.

Pediatric radiography differs from adult patients. They often do not cooperate during testing and are restless. If the position of these patients after positioning is not stabilized properly, a provided graph will not have required diagnostic quality.⁷ The infant rotation to one side is one of the most common positioning errors, which can lead to expanding images of the heart and mediastinum to the desired side and can largely cover that side of the lung parenchyma. In this case, evaluation of lung, heart and mediastinal disorders will be faced with problems and sometimes there is no choice but to repeat the test.⁵

If the positioning of the patient is optimally stabilized, proper collimation of imaging area will be possible, and thus the non-essential organs will not be in the radiation field and the dose received by the patient will be reduced. Moreover, the image contrast is improved due to the reduction of scattered rays.^{8,9}

On the other hand, the quality of improper radiographic positioning may result in repeated tests. The repeated test means re-exposure of the infant. However, the infants compared to adults are more sensitive to radiation damage so that the incidence of cancer in the infant in the same dose is 10-15 times more than a person with 50 years of age.¹⁰

Many believe that the dose received by portable X-ray of the lungs or abdomen of the infant is low.^{4,6} However, due to repetitively perform of the procedure during hospitalization of the infant as well as the high sensitivity of infants to the rays, doing optimization procedure, selecting proper method of imaging, appropriate positioning, stabilizing the position of an infant, adhering to protective principles and reducing the dose exposed to the infant are very important.⁸ Several factors raise the risk of radiation damages. Most of the baby's tissues and organs are developing, so the proportion of cells in mitosis is relatively high in them. On this basis, according to the law of Bergioner and Tribandeu, the infants in the

second place after the fetus will be most sensitive to radiation.¹¹ Age is another factor to increase the risk of radiation damages in this group of patients. Undoubtedly, they have many years of lifespan ahead, and this means more opportunity for radiation damages.^{10,12}

To reduce the dose received by the infant in a portable chest radiography, optimizing the conditions of exposure in accordance with the principle of ALARA (As Low As Reasonably Achievable), appropriate positioning, immobilizing the patient and tight collimation are very helpful.^{8,10}

Multiple sandbags or patients accompanies and sometimes both together often are used to stabilize the position of newborns for portable X-ray of the lungs. These methods usually have no proper efficiency incomplete stabilization of the infant and also may result in the exposure of the patient's accompany. Poor quality of position stabilizing in most cases leads to the baby's rotation and degrades the diagnostic quality of the graph so that stereotyped are sometimes difficult to interpret and repeated therapy is inevitable.

The use of a dedicated tool to stabilize the baby imaging can largely solve the problem of rotation.¹³ If such a tool can completely stabilize the baby, firstly there will be no need for the patient's accompanies during the radiography to help for stabilizing the baby so the patients accompany will not receive the radiation.; secondly, the baby's position during the radiography will change less and the graph will have less error in terms of positioning of the patients. In this case, repeated radiography because of the patient's rotation will be reduced remarkably.

Studies show that the use of infant immobilizer can help to optimize diagnostic and therapeutic procedures, including procedures for imaging in these patients.¹⁴⁻¹⁶

The aim of this study is to investigate the role of common procedures in order to stabilize the baby in the final quality of graph. For this purpose we used a dedicated body rest to stabilize newborns during chest radiography. It had different parts for head and limbs fixation.

OBJECTIVES

This study has focused specifically on pediatric portable chest radiography because this radiography is the most frequent diagnostic x-ray procedures in preterm infants hospitalized in intensive care units. Since the position of the baby and stabilization methods are pivotal factors in the final quality graph,¹⁷⁻¹⁹ so different methods of stabilization and their radiographic findings were evaluated in this study.

PATIENTS AND METHODS

The present study was conducted for 9 months on newborns admitted to the NICUs at four University Centers. The pediatric portable chest radiography including both sexes, different diseases and varying degrees of prematurity were studied in two groups. The first group consisting of 176 radiographs related to infants from three university hospitals was evaluated in terms of the newborn position during lung X-ray within a retrospective study. The group had an average weight of 2570gr and included both sexes. The common methods (sandbags or patient's accompanies or sometimes both) had been used to stabilize the baby's position in all these centers during radiography.

The second group including 74 radiographs was for infants referred to an academic center whose positions had been stabilized during X-ray using body immobilizer. The group had the average weight of 2630gr and involved infants of both sexes.

In both groups, the lung graphs were carried out through the portable X-ray devices in the neonatal intensive care unit. In each center, the studied graphs were performed by a variety of radiographers with varying degrees of experience.

A radiologist studied radiography of both groups. The radiologist was blind towards the groups. The radiologist measured separately the length of the left and right posterior ribs on each X-ray, recorded the findings, judged on the X-ray of rotation with sight and placed them in one of three groups of "no rotation", "minor rotation but with diagnostic value" and "serious rotation without diagnostic value".

The graphs of the three centers had been prepared using the film/screen system and the graphs related to a center had been obtained using computed radiography (CR) system.

The results were analyzed and differences between the length of right and left posterior ribs were calculated to assess the quantity of rotation factor in the radiographs and were considered as a basis. The ruler was applied in the graphs taken by film/screen system, and the tools for measuring the length in the toolbox of K-PACKS software were recruited in the graphs done by CR system.

RESULTS

In this study, the quality of positioning in terms of the infant rotation during portable lung X-ray was evaluated by comparing the length of posterior ribs. Pediatric portable X-rays from four academic centers in terms of stabilization of infant position during the portable lung X-ray were studied in two

groups. The general context of the study has been shown in flow chart [diagram 1](#).

The first group included 176 radiographs related to infants from three university hospitals that sandbags or patients accompanies had been used to stabilize the position of the patient, and the second group consisted of 74 radiographs associated with infants referred to the academic center whose positions had been stabilized during X-ray using body immobilizer. [Table 1](#) shows the results of comparing the differences in the length of posterior ribs in the two groups.

[Table 2](#) presents the number of samples and the mean differences in the length of posterior ribs separately for centers. The sandbags or patient's accompanies or both are utilized in the Centers 1, 2 and 3 to stabilize the baby's position during portable lung X-ray and the body immobilizer special for X-ray was applied for the Center 4.

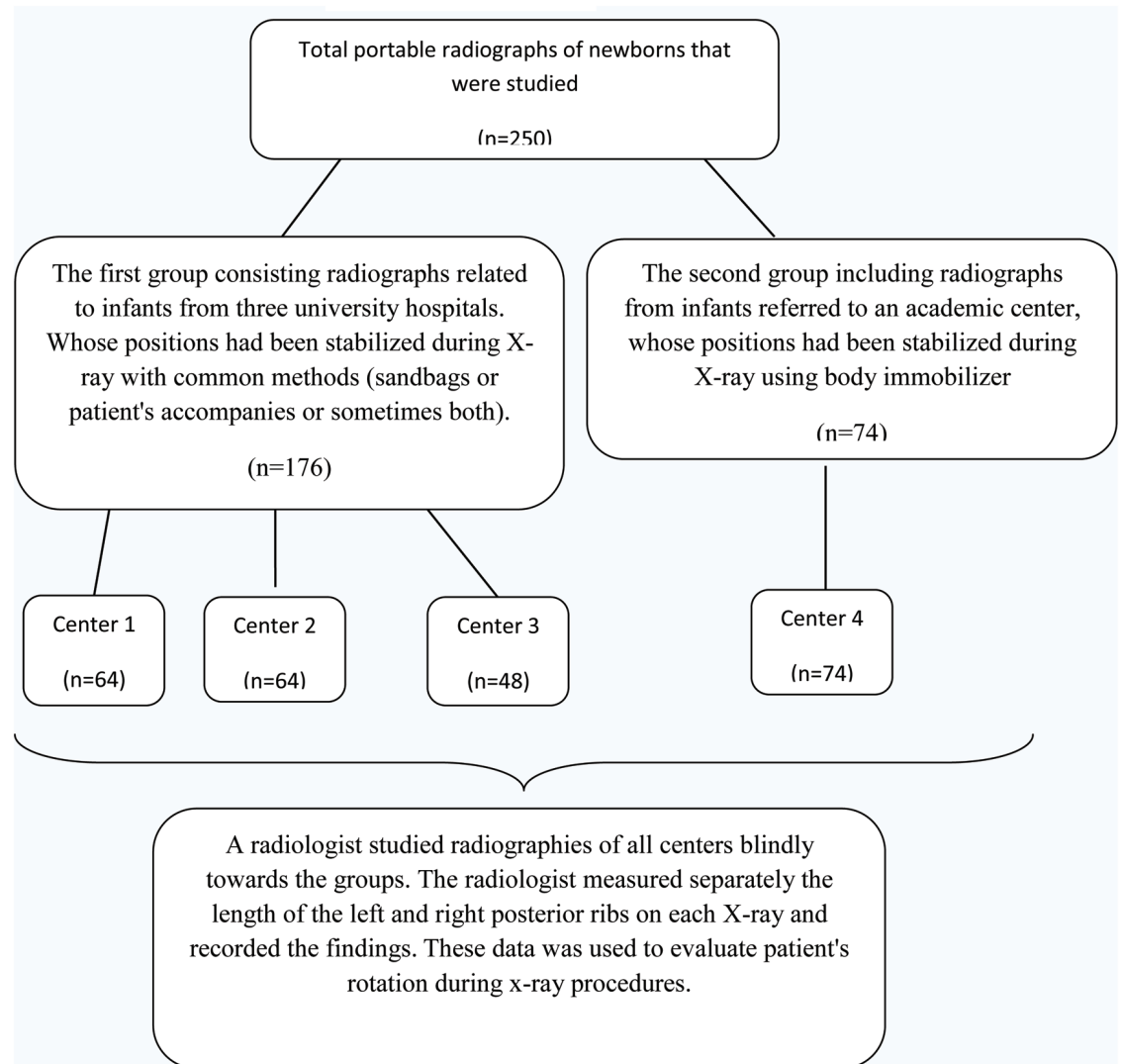
The graphs in the Centers 1, 2 and 4 were taken using film/screen system, while the computed radiography system was used in the Center 3. However, the mean differences in the length of posterior ribs at the Center 3 were not significant compared with the Centers 1 and 2. This means that the method of imaging had no effect on the infant rotation factor ([Table 2](#)).

However, comparing the mean differences in the length of posterior ribs in the graphs of the Center 4 showed significant difference with the other three centers. The mean difference in the length of posterior ribs was 2.87 ± 2.15 mm in this center. The reason for this difference and thus a significant reduction in the infant rotation compared to the standard position is in the stabilization methods during the neonatal radiography ([Table 3](#)).

The graphs in the Center 4 were taken using film/screen system. In the center, the conditions of the device, the distance of the tube and equipment required for X-ray including immobilizer were quite ready and set. Then, to perform lung radiography, the infant was transferred to the immobilizer and the position was stabilized by different parts of the immobilizer special for radiography. The baby's head was firmly stabilized by two lateral pads and an adhesive tape, and each of peripheral organs of the infant using adhesive tape and lateral pad of the immobilizer so that the infant position remained almost constant throughout the X-ray. Thus, there was no need for sandbags or patients accompany to maintain the position of the patient. After the radiography, the infant was immediately detached from the immobilizer and returned to the incubator.

Qualitative analysis of rotation factor by a radiologist and without measuring the length of the posterior ribs in the four centers shows that the use

Flow chart diagram 1

**Table 1** Shows the results of comparing the differences in two groups

Differences in the length of posterior ribs	Statistical parameters	
	Mean ± SD	Independent t-test
Group 1	6.51±5.05	P<0.0001
Group 2	2.87±2.15	

Table 2 Presents the number of samples and the mean differences in the length of posterior ribs separately for centers

Center	Mean	N	Std. Deviation	Variance	% of Total Sum
Center 1	5.9844	64	5.18696	26.905	28.0%
Center 2	6.9219	64	5.54149	30.708	32.4%
Center 3	6.8125	48	4.13936	17.134	23.9%
Center 4	2.8784	74	2.15147	4.629	15.6%
Total	5.4640	250	4.70332	22.121	100.0%

Table 3 Presents the mean differences and Std. in different centers

Multiple Comparisons			
Centers	Mean Difference	Std. error	Sig.
Center 1	-3.10600*	.75189	.000
Center 2	-4.04350*	.75189	.000
Center 3	-3.93412*	.81632	.000

*. The mean difference is significant at the 0.05 level.

Table 4 Presents various rotation rates in different centers

Centers	Rotation Factor	Rotation			Total
		No rotation	rotation with diagnostic value	rotation without diagnostic value	
Center	1	38	18	8	64
	2	27	24	13	64
	3	21	21	6	48
	4	62	12	0	74
Total		148	75	27	250

of this tool has played a significant role in reducing infant rotation and improving the positioning (Table 4).

During the study, no X-ray was repeated in the Center 4 due to position error and high rotation.

DISCUSSION

The pediatric portable radiography is the most frequent diagnostic x-ray procedures that can reveal a wide range of diseases and disorders in thoracic and mediastinal areas, provided that the x-ray has required diagnostic quality. Factors affecting the quality radiographs are numerous, such as the use of proper exposure technique, positioning, methods of infant stabilization and suitable method of imaging.

Suitable position and stabilization of the infants can be very effective in imaging findings. The standard position and stabilization prevent the repetition of radiography due to the rotation as well as contribute to improving diagnostic details of lung imaging. The sandbags or patient's accompanies or both are used to stabilize the baby in most centers. Our study indicates that these methods are usually associated with some degree of rotation for children, have no good efficiency, and make exposure of the patients accompanies. As an alternative approach, a special type of body immobilizer was employed in this project and has yielded good results and the mean rotation of the infant was reduced significantly after positioning by the radiographer. The use of this immobilizer, in addition to improving the positioning of the baby, had other advantages:

- 1) The use of this device is very convenient, speeding up the processes of positioning and stabilization.
- 2) There was no need for assistance of patient's accompanies in any of the graphs, so none of the patients accompanies received radiation because of helping to do portable X-ray.
- 3) No effect was reported damages to the infants caused by the use of the device during the study.

Because the reader was blind to groups, it is unlikely that bias in data collection was arisen. We had a limitation in this study. A few babies were premature and so weak. They were in a serious condition, with a lot of vital equipment attached to them. We could not use body rest for them.

CONCLUSION

The pediatric radiography is always a challenging issue. These patients are unable to cooperate and usually are restless during radiography. In the centers, which use the sandbags or accompanies to stabilize the infant position during the radiography, some degrees of infant rotation and thus drop in the diagnostic value of radiography can be seen. The current study indicated that the use of an auxiliary tool in stabilizing the child during radiography could help effectively to improve the positioning of the baby during portable radiography. In addition, the need for assistance of accompanies and their exposure can be eliminated. No radiography was repeated due to position error and high rotation.

CONFLICTS OF INTEREST

The authors declare no conflict of interest.

FUNDING/SUPPORT

This work was supported by the office of vice president for research in Gonabad University of Medical Sciences.

REFERENCES

1. Yu C-C. Radiation safety in the neonatal intensive care unit: too little or too much concern? *Pediatrics & Neonatology*. 2010;51(6):311-9.
2. Ono K, Akahane K, Aota T, Hada M, Takano Y, Kai M, et al. Neonatal doses from X-ray examinations by birth weight in a neonatal intensive care unit. *Radiation protection dosimetry*. 2003;103(2):155-62.
3. Donadieu J, Zeghnoun A, Roudier C, Maccia C, Pirard P, André C, et al. Cumulative effective doses delivered by radiographs to preterm infants in a neonatal intensive care unit. *Pediatrics*. 2006;117(3):882-8.
4. Toossi MTB, Malekzadeh M. Radiation dose to newborns in neonatal intensive care units. *Iranian Journal of Radiology*. 2012;9(3):145.
5. Frank ED, Long BW, Smith BJ. *Merrill's Atlas of Radiographic Positioning and Procedures-E-Book*: Elsevier Health Sciences; 2013.
6. Foos DH, Yankelevitz DF, Wang X, Berlin D, Zappetti D, Cham M, et al. Improved visualization of tubes and lines in portable intensive care unit radiographs: a study comparing a new approach to the standard approach. *Clinical Imaging*. 2011;35(5):346-52.
7. Dougeni E, Delis H, Karatza A, Kalogeropoulou C, Skiadopoulos S, Mantagos S, et al. Dose and image quality optimization in neonatal radiography. *The British journal of radiology*. 2014.
8. Willis CE. Optimizing digital radiography of children. *European journal of radiology*. 2009;72(2):266-73.
9. Soboleski D, Theriault C, Acker A, Dagnone V, Manson D. Unnecessary irradiation to non-thoracic structures during pediatric chest radiography. *Pediatric radiology*. 2006;36(1):22-5.
10. Alzen G, Benz-Bohm G. Radiation protection in pediatric radiology. *Deutsches Ärzteblatt International*. 2011;108(24):407.
11. Hall EJ. Lessons we have learned from our children: cancer risks from diagnostic radiology. *Pediatric radiology*. 2002;32(10):700-6.
12. Suleiman OH. Radiation doses in pediatric radiology: influence of regulations and standards. *Pediatric radiology*. 2004;34:S242-S6.
13. Aldrich JE, Duran E, Dunlop P, Mayo JR. Optimization of dose and image quality for computed radiography and digital radiography. *Journal of digital imaging*. 2006;19(2):126-31.
14. Golan A, Marco R, Raz H, Shany E. Imaging in the newborn: infant immobilizer obviates the need for anesthesia. *IMAJ-Israel Medical Association Journal*. 2011;13(11):663.
15. Reilly L, Byrne AH, Ely E. Does the use of an immobilizer provide a quality MR image of the brain in infants? *Journal of radiology nursing*. 2012;31(3):91-6.
16. Carmichael J. *European guidelines on quality criteria for diagnostic radiographic images: Office for Official Publications of the European Communities*; 1996.
17. Cook J, Pettett A, Shah K. *Guidelines on Best Practice in the X-ray Imaging of Children. A Manual for all X-ray Departments*. 1998.
18. Goske MJ, Applegate KE, Boylan J, Butler PF, Callahan MJ, Coley BD, et al. The Image Gently campaign: working together to change practice. *American Journal of Roentgenology*. 2008;190(2):273-4.
19. Cook J, Kyriou J, Pettett A, Fitzgerald M, Shah K, Pablot S. Key factors in the optimization of paediatric X-ray practice. *The British journal of radiology*. 2001;74(887):1032-40.



This work is licensed under a Creative Commons Attribution