

## Cervical myelopathy due to an endodermal intraspinal cyst in a two-year-old child: a case report



Jainal Arifin<sup>1</sup>, Karya Triko Biakto<sup>1</sup>, Putu Acarya Nugraha Winangun<sup>2\*</sup>

### ABSTRACT

**Background:** Cervical myelopathy is commonly seen in the older population caused by a degenerative process, but in a rare case, it can be seen in the pediatric population due to uncommon causes, such as an intraspinal cyst. This case report aims to discuss a rare case of cervical myelopathy due to an endodermal cyst in a two-year-old child.

**Case Presentation:** A 2-year-old child with limited neck movement and abnormal body posture from 6 months before admission to the hospital. Spine trauma and other histories of disease were denied. There was no deformity, swelling, hematoma, and wound on the vertebra region from physical examinations. The motoric function was found weaker on the upper and lower right extremities, and pathological reflex was found on both sides. MRI examination showed an intradural extra-medullary space-occupying lesion on the C2-C5 level of the spine. At first, the patient was diagnosed with cervical myelopathy due to an intradural extramedullary tumor at level C2-C5. Excision of the cyst, posterior decompression, and laminectomy was done in this patient. The postoperative histopathological result showed an intraspinal cyst with an endodermal type cyst.

**Conclusion:** This case study was first diagnosed due to an intradural extramedullary tumor, which appears to be a benign intraspinal cyst from the histopathological result. The surgical treatment results in a favorable outcome, but a routine follow-up should monitor the improvement or long-term neurological decline.

**Keywords:** Cervical Myelopathy, Endodermal, Intraspinal, Spine Tumor.

**Cite This Article:** Arifin, J., Biakto, K.T., Winangun, P.A.N. 2021. Cervical myelopathy due to an endodermal intraspinal cyst in a two-year-old child: a case report. *Bali Medical Journal* 10(3): 950-955. DOI: 10.15562/bmj.v10i3.2785

<sup>1</sup>Spine Consultant, Department of Orthopaedic and Traumatology, Universitas Hasanuddin, Wahidin Sudirohusodo Hospital, Makassar, Indonesia;

<sup>2</sup>Resident of Orthopaedic and Traumatology, Universitas Hasanuddin, Wahidin Sudirohusodo Hospital, Makassar, Indonesia;

\*Corresponding author:

Putu Acarya Nugraha Winangun;  
Resident of Orthopaedic and Traumatology, Universitas Hasanuddin, Wahidin Sudirohusodo Hospital, Makassar, Indonesia;  
[putuanw@gmail.com](mailto:putuanw@gmail.com)

Received: 2021-10-12

Accepted: 2021-11-26

Published: 2021-12-07

### INTRODUCTION

Cervical myelopathy refers to a condition where there is a cord compression in the cervical spine. Cervical myelopathy is commonly seen in older populations due to the degenerative process.<sup>1,2</sup> In rare cases, cervical myelopathy can also be found in younger populations, such as pediatric patients. An intraspinal cyst is the most frequent uncommon cause of cervical myelopathy in pediatric populations.<sup>3</sup>

The symptoms of cervical myelopathy usually develop slowly progressively. There may be a time gap between the onset of the disease and the first treatment due to the lack of pain.<sup>1,2</sup> The symptoms of cervical myelopathy due to intraspinal cysts include a problem with fine motor skills, numbness and weakness in hands and foot, decreased range of motion in the cervical spine, pain in shoulder and arms, and unsteady or clumsy gait.<sup>1,2</sup> The

other clinical findings are the extremity's weakness or decreasing motoric function and the presence of pathological reflex. A benign intraspinal cyst is the most frequent unusual cause of symptomatic cervical spine compression.<sup>1,2</sup> There are various cystic lesions in the cervical spinal canal, such as arachnoid cysts, ependymal cysts, neurenteric cysts, teratogenous, and epithelial cysts. These cysts have in common a congenital origin, with the possible exception of a small number of arachnoid cysts, which may appear after trauma and or arachnoiditis.<sup>3,4</sup> These cysts produce their effects as a result of spinal cord compression, and therefore most frequently present as slowly progressive myelopathy or myeloradiculopathy.<sup>3</sup>

Neuroimaging procedures such as magnetic resonance imaging (MRI) are the first supporting examination that can be done to evaluate an intraspinal cyst.

This examination greatly enhanced our diagnostic capabilities for recognizing cyst lesions.<sup>1,5</sup> Once the diagnosis has been established by MRI, surgery is usually performed to prevent further spinal cord or nerve root compression. Symptomatic cysts should be resected entirely whenever possible; those not amenable to excision should be widely fenestrated into the subarachnoid space. The modality treatment for this condition is surgery by decompression and laminectomy to remove the cyst.<sup>5</sup> In this case report, we will discuss a rare case of cervical myelopathy due to a benign intraspinal cyst found in a two-year-old child diagnosed as cervical myelopathy due to an intradural extramedullary tumor. This case report will highlight the clinical presentation, histological characteristics, imaging findings, surgical management, and patient outcome after surgery.

## CASE REPORT

We reported a case of a two-year-old child patient with a complaint of limited neck movement and abnormal body posture six months before admission to the hospital. Abnormal body posture was reported by the parents when the patient was standing and walking. The parents also noticed a gait imbalance in the patient. The patient's body posture can be seen in [Figure 1](#). The parents denied spine trauma and other histories of disease. The other complaints, such as fever or other infections, were also denied. The patient's urination and defecation were reported as normal. History of prior surgery and systemic illness was also denied. From the neonatal history, the patient was aterm at birth with a birth weight of 2.8 kilograms and

no congenital defect at birth. The patient's immunization status was incomplete.

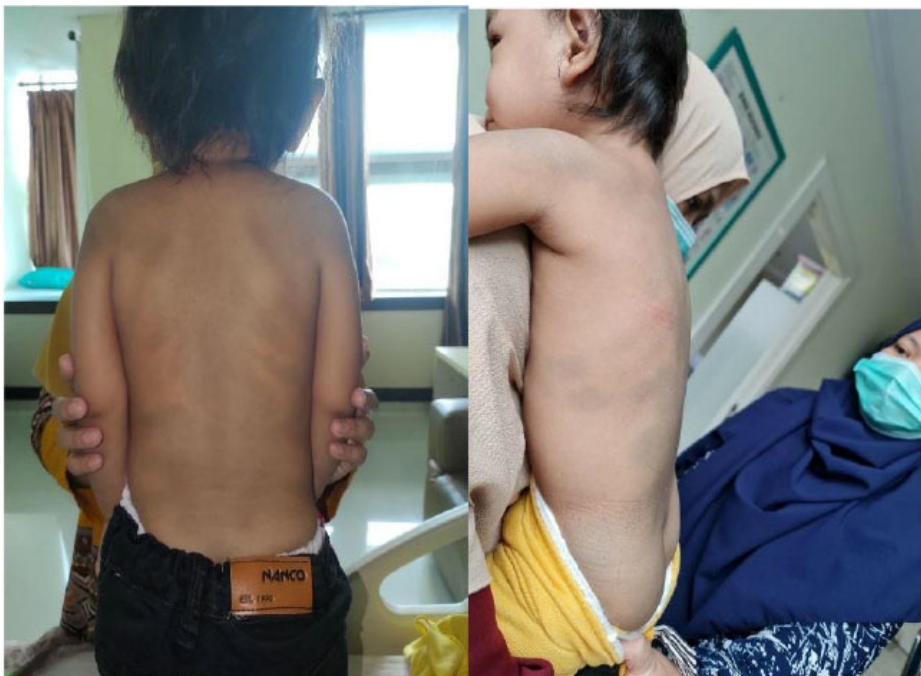From general physical examinations, the patient was in good condition with a heart rate of 110x/minute, a respiration rate of 28x/minute, an axilla temperature of 36.7°C and the patient's body weight was 11 kilograms. From the local examination on the vertebral region, we found no deformity, swelling, hematoma and wound, and no tenderness on palpation from inspection. The motoric function was found weaker on the right extremities. Pathological reflexes such as Hoffman, Tromner, Babinsky, Chaddock, Oppenheim and clonus were found positive on both sides of extremities. The physiological reflexes were within the normal condition. The sensory function cannot be evaluated due

to the patient not cooperative. Several supporting examinations were also done on this patient. Complete blood count examination was within the normal limit ([Table 1](#)).

Chest radiography examinations showed no abnormality in the lungs and no bony abnormalities. The abdominal and cervical x-ray also showed no abnormality, as we can see in [Figure 2](#). The vertebra's magnetic resonance imaging (MRI) examination was seen as an intradural extra-medullary space-occupying lesion with size 2.8 cm x 2 cm x 2.8 cm on the C2-C5 level of the spine with characteristic supporting a schwannoma, as we can see in [Figure 3](#). From MRI result also showed mild canal stenosis on levels C2-C5 of the spine. On the pre-surgery patient was diagnosed with cervical myelopathy due to an intradural extramedullary tumor at level C2-C5.

The patient was done elective surgery in the prone position under general anesthesia. The surgery was decompression, posterior stabilization and laminoplasty, as seen in [Figure 4](#). After laminectomy, a cystic lesion measuring 0,8cm x 1cm was eradicated with its capsule ([Figure 4C](#)) and the specimen was submitted for histopathological examination. The histopathological result showed a benign intraspinal cyst. Thus the post-surgery diagnosis changed into cervical myelopathy due to benign intraspinal cyst with endodermal type cyst.

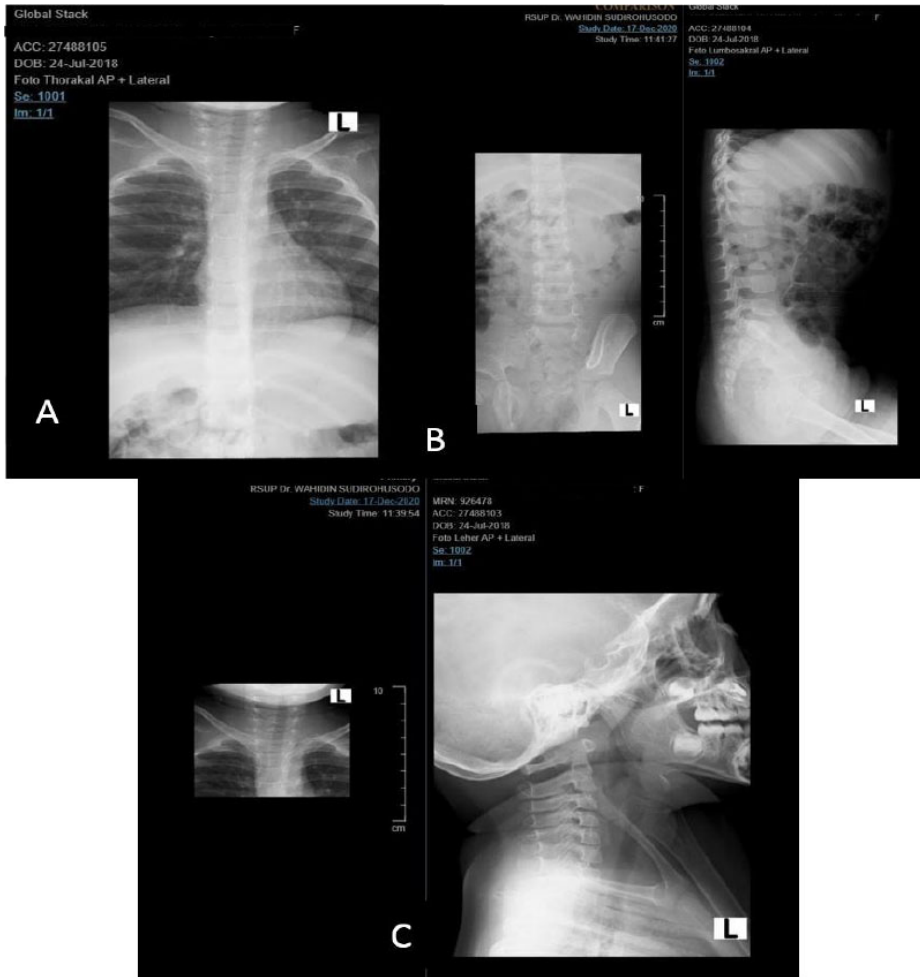
On the first day post-surgery, the patient was in a good and stable condition with vital signs within normal limits. The parents reported that both lower extremities could move freely, but the upper extremities were still limited. The wound was good, and the drain was discharged, as shown in [Figure 5](#). The patient was treated with intravenous fluid, intravenous paracetamol as an analgesic, Ceftriaxone injection for antibiotics and wound care. The patient had an uneventful postoperative course and was discharged from the hospital on the third day. At a follow-up visit one month later, the patient's symptoms were improved. There was still weakness on the right hand, but better than pre-surgery condition. Her gait imbalance and body posture also



**Figure 1.** Patient's clinical picture before surgery.

**Table 1.** Patient's pre-surgery complete blood count result.

Parameter	Results	Parameter	Results
WBC ( $10^3/\mu\text{L}$ )	5.9	CT (second)	8.3
RBC ( $10^6/\mu\text{L}$ )	4.76	RBS (mg/dL)	125
Hb (g/dL)	13.00	SGOT (U/L)	37
HCT (%)	37	SGPT (U/L)	16
PLT ( $10^3/\mu\text{L}$ )	277	BUN (mg/dL)	25
PT (second)	10.9	Creatinine (mg/dL)	0.30
INR	1.05	Natrium (mmol/L)	134
APTT (second)	31.7	Kalium (mmol/L)	4.4
BT (second)	2.3	Chloride (mmol/L)	105



**Figure 2.** Patient's radiographic examination results. (A) Chest x-ray result; (B) Abdominal x-ray result; and (C) Cervical x-ray result.

improved compared with the pre-surgery condition.

## DISCUSSION

In this case report, we presented a two-year-old child with limited neck movement and abnormal body posture reported by the parents six months ago. The patient was initially diagnosed with cervical myelopathy due to an intradural extramedullary tumor's physical and radiological examinations. But then, histopathological examination revealed a benign intraspinal cyst with endodermal type as the cause of the cervical myelopathy. The cervical spine is contained of seven vertebrae from C1-C7 with six intravertebral discs and eight nerve roots. The spinal cord is laid inside the vertebral column from the vertebrae's anterior part cushioned by intervertebral

discs from the posterior by the facet joints and lamina. Cervical nerve roots branch out and primarily control the function of shoulders, arms and hands.<sup>1,2</sup> Cervical myelopathy is a condition when the cervical spinal cord is compressed.<sup>1,5</sup> The compression in cervical myelopathy is usually caused by a degenerative process, but sometimes it also can be caused by a rare condition such as a cyst or tumor.<sup>1,6</sup> From the prevalence, cervical myelopathy is usually found in persons older than 55 years old.<sup>1,2</sup> But this condition also can be found at a younger age and even in pediatric cases besides degenerative processes, such as cyst or tumor. A benign intraspinal cyst is the most frequent unusual cause of symptomatic cervical spine compression.<sup>4</sup> There are various cystic lesions in the cervical spinal canal, such as arachnoid cysts, ependymal cysts, enterogenous or neurenteric cysts, teratogenous cysts and

epithelial cysts.<sup>4,6</sup>

In this case report, cervical myelopathy was found in a two-year-old girl with abnormal body posture symptoms when standing and walking and the limited neck movement that the parents reported. Most patients with symptomatic intraspinal cyst have signs and symptoms of spinal cord compression that are indistinguishable from other causes of compressive myelopathy such as primary or metastatic tumors, herniated disc or spondylitis disease. The symptoms of cervical myelopathy are a problem with fine motor skills, numbness and weakness in hands and foot, decreased range of motion in the cervical spine, pain in the shoulder and arms, and unsteady or clumsy gait. The symptoms we found in this patient was corresponding with the sign and symptoms of cervical myelopathy. The most common clinical findings of cervical myelopathy due to intraspinal cyst is the insidious onset that is slowly progressive.<sup>5,7</sup> Due to lack of pain, there may be an interval of time between the onset of the disease and first treatment. In our case, there is a six-month gap between the first symptoms and the first treatment.<sup>1</sup> This is caused by the patient being a pediatric patient; she has not yet described the painful feeling. Thus the parents are a bit late to recognize the abnormality of their child. Early symptoms of cervical myelopathy condition are numb, clumsy hands and disturbance of fine motor skills. In this case, the parents reported limited neck movement in their child. This can be caused due to neck pain that decreases the range of motion, especially extension. The other symptoms were abnormal body posture, weakness in the right extremities, and numbness in cervical myelopathy condition in a non-specific or non-dermatomal pattern.<sup>5,7</sup> As the cord compression occurred, the lower motor neuron findings in the upper extremities may be present, such as loss of strength, muscle atrophy, and fine movement difficulties. The atrophy and decreased extremity weakness can cause abnormal or imbalance body posture, as we found in our patient.<sup>5,7,8</sup>

We found additional clinical findings in our patients were the presence of pathological reflexes such as Hoffman Tromner reflex, Babinski reflex, Chaddock



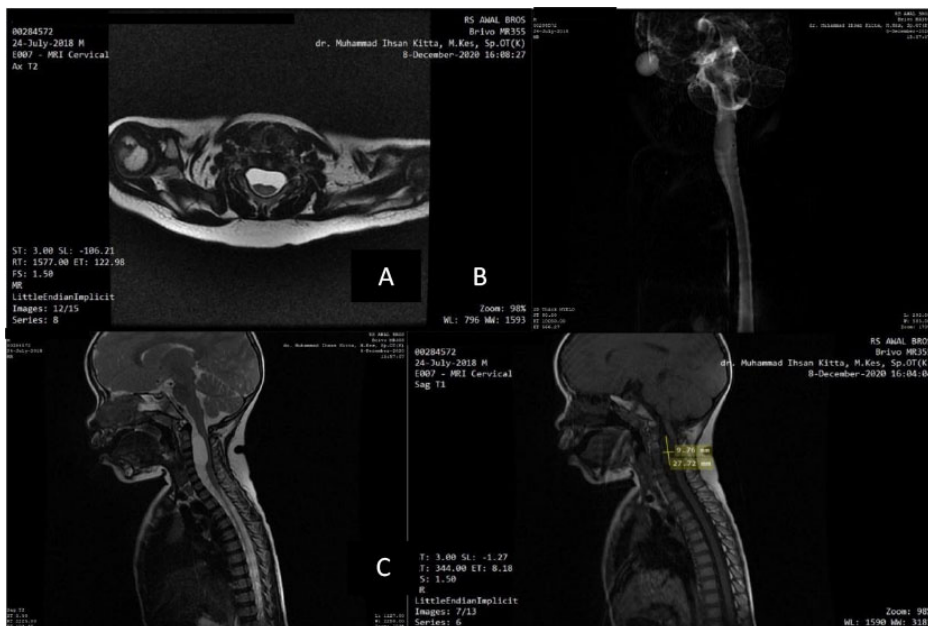
reflex, Oppenheim reflex, and clonus reflex on both extremities. This corresponds with clinical findings in cervical myelopathy patients, which is the presence of

pathological reflex are typical neurological signs of long-tract involvement besides exaggerated tendon reflexes (patellar and Achilles), sensory loss and bladder-bowel

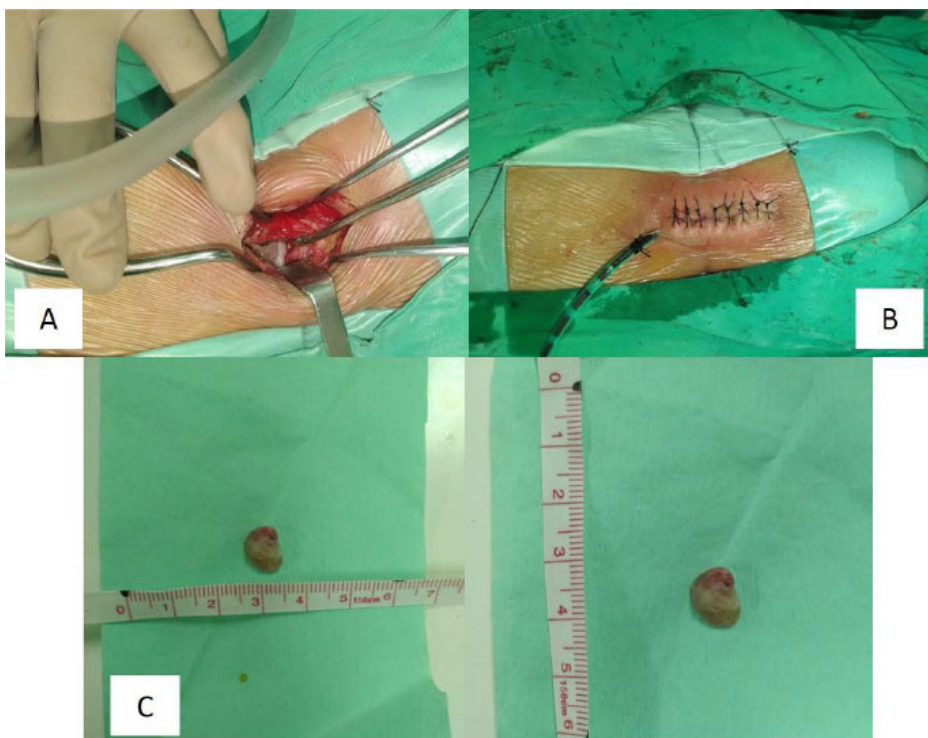
disturbance.<sup>5,9</sup> In our case report's patient, we cannot evaluate the sensory function because the patient was not cooperative. At the same time, her bladder-bowel function is still normal.

Magnetic resonance imaging examination is the first line supporting examination that can be done to establish the cause of cervical myelopathy. In our patients, MRI results showed an intradural extra-medullar space-occupying lesion with size 2.8 cm x 2 cm x 2.8 cm on the C2-C5 level of the spine with characteristics supporting a schwannoma and mild canal stenosis on level C2-C5 of the spine. MRI is the imaging modality of choice as it can accurately localize the space-occupying lesions and show the size and degree of neural tissue compression. Besides MRI, our patients have also done other examinations such as complete blood count, chest, cervical and abdominal x-ray with no abnormality signs.<sup>10,11</sup> In our case, there was no corresponding findings between MRI results and histopathological result. The MRI examinations found the cause of the cervical myelopathy is an intradural extramedullary tumor that tends to be a schwannoma, while the histopathological result found a benign intraspinal cyst.

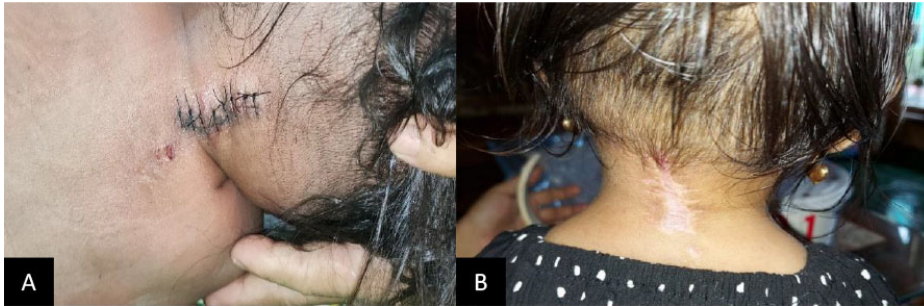The histopathologic findings in our case report showed tissues containing connective tissue with cyst structure and a simple layer of cylindrical epithelial cells with an atypical nucleus that concluded as a benign intraspinal cyst with endodermal type. The clinical and radiologic differential diagnosis of intraspinal cyst lesions includes synovial cyst, ganglion cyst, Tarlov's perineural cyst, extradural arachnoid cyst, dermoid cyst, ependymal cyst and neurenteric cyst.<sup>5,12</sup> The type of intraspinal cysts of this case report has not been specified. The cyst type of our case is an endodermal cyst. This finding is suitable with the characteristic of the cyst that has epithelial lining. Endodermal cysts occur most frequently in the spinal canal, mainly in the lower cervical and upper thoracic spine. The typical presentation is an intradural and extramedullary cystic mass compressing the spinal cord from the ventral aspect, similar to what was seen in the present case. Differential diagnosis includes arachnoid and epidermoid cyst.



**Figure 3.** Patient's magnetic resonance imaging results. (A) MRI result from axial view showed a lesion in canalis cervical (B) MRI result with contrast, (C) MRI result from sagittal view showed a lesion on the C2-C5 level of the spine.



**Figure 4.** (A) and (B) Patient's clinical picture during surgery; (A) showed cyst dissected from the dura; and (C) Intraspinous cyst obtained from surgery with size 1 x 0.8 cm.



**Figure 5.** The patient's surgery wound on the first day after surgery (A) and one month after surgery (B).

They are characterized histologically by the cyst wall was composed of a loose, thin, fibrous membrane containing melanocytes and was intermittently lined with flattened or partially cuboidal epithelial cells.<sup>11</sup> Although a congenital lesion, an endodermal cyst is frequently diagnosed in adulthood, usually during the third decade. However, it can present at any age. Endodermal cyst presumably results from the abnormal separation of neuroectodermal and endodermal layers during the third week of embryogenesis. Adhesions between these two germ cell layers are probably responsible for complex malformations of the spinal cord, spine, and viscera as well.<sup>11,12</sup>

Although histologically benign, they can bring about significant neurological deficits if detection and treatment are delayed. The spinal endodermal cysts may be associated with various other congenital spinal anomalies.<sup>11</sup> The other type of cyst, synovial cyst, develops from a facet joint, is usually on the posterolateral aspect of the dural sac, contains mucinous fluid, and has synovial lining cells in its wall. An intraspinal synovial cyst can be differentiated from a disk cyst by location. Intraspinal ganglion cysts, the origin of which is disputed, are usually referred to as cysts arising from the facet joints of the lumbar spine and are found in the dorsolateral epidural space. Histologically, the wall of a ganglion cyst is made up of connective tissue without synovial lining cells.<sup>13,14</sup>

The pathophysiology of intraspinal cyst is still unknown, but some hypotheses have been suggested. One theory stated that cysts caused by epidural hematoma because cysts contained hemorrhagic fluid

were found in four of seven cases reported by Yuceer N et al.<sup>6</sup> This theory said epidural hematoma is produced by rupture of the epidural vein due to mechanical irritation from a herniated disk.<sup>6</sup> Another hypothesis stated that intraspinal cyst resulted from focal degeneration and cystic softening of the disk's collagenous connective tissue with fluid production, like cyst formation in meniscal degeneration of the knee.<sup>6</sup> The reactive pseudo-membrane formation then developed and encapsulated the fluid. The histologic findings of the cyst wall showed fibrous structure without synovial lining cells.<sup>6</sup>

A study conducted by Bond AE et al., stated that the initial formation of an intraspinal cyst is likely multifactorial and is not completely understood.<sup>9</sup> A previous study proposed an origin from congenital diverticula or a congenital dural defect with herniation of the arachnoid.<sup>13</sup> Support for the congenital theory is further strengthened by a few case reports of familial tendencies and the frequency of association with neural tube defects. Other reports have hypothesized that congenital defects in the distribution of arachnoid trabeculations lead to misplaced cellular remnants resulting in an embryonic malformation, which may act as a nidus for cyst formation.<sup>3,4</sup> But for patients with no significant medical history, like the patient in this case report, we can assume these cysts are primary in nature.

Once the diagnosis of cervical myelopathy and the cause has been established, surgery must prevent further damage of cord compression. Symptomatic cysts should be resected entirely whenever possible; those not amenable to excision should be widely

fenestrated into the subarachnoid space. The principal aim of surgery for cervical myelopathy is decompression of the spinal cord.<sup>4,5</sup> Surgical techniques include multi-level discectomies or corpectomies with or without instrumented fusion, laminectomy with or without instrumented fusion or laminoplasty. Surgical decompression is generally considered if the symptoms affect daily life, but early surgical intervention is more effective. Therefore, early detection may be the key to minimizing postoperative degeneration.<sup>7,10</sup> In our case, the patient was done decompression, posterior stabilization and laminoplasty under general anesthesia in a prone position.

In this patient, decompression and laminectomy at level C2-C5 were performed to expose the intradural extramedullary cyst. Careful dissection and complete excision of the cyst were done. As shown in the case study, the obtained intraspinal cyst has round-shaped with white-yellowish color and milky white contents. The cyst we found in our patient is located posteriorly. Thus a complete dissection can be done through the posterior approach without affecting the spinal cord and causing injury. Based on the previous study, if the cyst is located ventrally, an aggressive removal through a posterior approach may result in spinal cord injury. Ventrally located intradural cysts such as arachnoid cysts, epithelial cysts, or ependymal cysts are frequently not amenable to complete resection without undue manipulation of the cord. In such cases, complete resection can be achieved. However, this is not always the case because the cysts' contents are irritants and cause adhesions when released into the subarachnoid space. This can create difficulty and prevent complete excision.<sup>14</sup>

The prognosis of benign intraspinal cyst is usually good due to the benign condition. But in common, depending on the cyst's location and the duration and degree of spinal cord compression, postoperative outcomes vary substantially. Some degree of improvement is reported in 45%–70% of cases following surgery, and complete elimination of symptoms is reported in 20%–30% of cases. Osenbach RK et al. stated that the majority of

patients with intradural spinal cysts realize a favorable outcome in terms of pain reduction and improvement in neurological function; however, the long-term neurological outcome reported in the literature has been variable, with some patients suffering long-term deterioration for no apparent reason after an excellent early result reported excellent sustained neurological outcome in all patients.<sup>2</sup> The recurrence has rarely been reported in the literature. The recurrence rate was 37% in the series by Oyemolade TA et al., and the interval between the initial surgery and recurrence was 4-14 years.<sup>8</sup> In contrast, Liu JK et al., reported no recurrence in any of their eight patients during a mean period of 38 months.<sup>7</sup> Nabors et al. have reported excellent results initially, with some patients suffering long-term neurological deterioration without evidence of cyst recurrence.<sup>3</sup> In our case, the patient's condition after one-month follow-up showed an improvement in her body posture and gait imbalance. We observed a much better body posture in that pre-surgery condition and also her gait was getting better. The patient now could walk and normally run, although it is still a little bit imbalanced. There is still weakness in her right extremities, but it improved than the pre-surgery condition. A careful and routine long-term monitoring should be done to evaluate any recurrence, neurological defect, failed improvement or long-term neurological decline that can be happened in the future.

## CONCLUSION

This case report showed a rare case of cervical myelopathy in a two-year-old child that at first diagnosed due to intradural-extramedullary tumors and subsequently changed due to benign intraspinal cyst based on the histopathological result. Although intradural spinal cysts are not common, they are important in the differential diagnosis of slowly progressive

myelopathy, especially in younger patients. The surgeon needs to differentiate between cervical spine disease that can be managed conservatively and that associated with neurological symptoms suggestive of more serious disease.

## CONFLICT OF INTEREST

There is no competing interest regarding the case study.

## ETHICS CONSIDERATION

This case study has followed the COPE and ICMJE protocols based on the publication ethics guidelines as well as received informed consent prior to the study being conducted.

## FUNDING

None.

## AUTHOR CONTRIBUTIONS

All authors contribute equally to the study from the conceptual framework, data acquisition, and data analysis until reporting the case study outcome through publication.

## REFERENCES

1. McCormick JR, Sama AJ, Schiller NC, Butler AJ, Donnally CJ 3rd. Cervical Spondylotic Myelopathy: A Guide to Diagnosis and Management. *J Am Board Fam Med.* 2020;33(2):303-313.
2. Osenbach RK, Godersky JC, Traynelis VC, Schelper RD. Intradural extramedullary cysts of the spinal canal: clinical presentation, radiographic diagnosis, and surgical management. *Neurosurgery.* 1992;30(1):35-42.
3. Nabors MW, Pait TG, Byrd EB, et al. Updated assessment and current classification of spinal meningeal cysts. *J Neurosurg.* 1988;68(3):366-377.
4. Goyal RN, Russell NA, Benoit BG, Belanger JM. Intraspinal cysts: a classification and literature review. *Spine (Phila Pa 1976).* 1987;12(3):209-213.

5. McCartney S, Baskerville R, Blagg S, McCartney D. Cervical radiculopathy and cervical myelopathy: diagnosis and management in primary care. *Br J Gen Pract.* 2018;68(666):44-46.
6. Yüceer N, Ozer E, Koyuncuoglu M. Spinal enterogenous cysts in infants. *European Journal of General Medicine.* 2006;3(4):193-196.
7. Liu JK, Cole CD, Kan P, Schmidt MH. Spinal extradural arachnoid cysts: clinical, radiological, and surgical features. *Neurosurg Focus.* 2007;22(2):E6.
8. Oyemolade TA, Adeolu AA, Idowu OK. Spinal extradural arachnoid cyst in a child-a case report. *J Surg Case Rep.* 2019;2019(10):rjz283.
9. Bond AE, Zada G, Bowen I, McComb JG, Krieger MD. Spinal arachnoid cysts in the pediatric population: report of 31 cases and a review of the literature. *J Neurosurg Pediatr.* 2012;9(4):432-441.
10. Nizami FA, Mustafa SA, Nazir R, Salaria H, Singh GP, Gadgotra P. Intradural extramedullary spinal cord tumors: surgical outcome in a newly developed tertiary care hospital. *International Journal of Scientific Study.* 2017;5(9):48-53.
11. Kikkawa Y, Nakamizo A, Suzuki SO, Tanaka S, Tsuchimochi R, Amano T, et al. Spinal endodermal cyst resembling an arachnoid cyst in appearance: Pitfalls in intraoperative diagnosis of cystic lesions. *Surg Neurol Int.* 2012;3:78.
12. Cai C, Shen C, Yang W, Zhang Q, Hu X. Intraspinal neurenteric cysts in children. *Can J Neurol Sci.* 2008;35(5):609-615.
13. Chimento GF, Ricciardi JE, Whitecloud TS 3rd. Intraspinal extradural ganglion cyst. *J Spinal Disord.* 1995;8(1):82-85.
14. Satyarthee GD. Pediatric Symptomatic Sacral Extradural Arachnoid Cyst: Surgical Management Review. *J Pediatr Neurosci.* 2018;13(2):211-213.



This work is licensed under a Creative Commons Attribution